

Virtual vs. optical colonoscopy in symptomatic gastroenterology out-patients: the case for virtual imaging followed by targeted diagnostic or therapeutic colonoscopy¹

M. BOSE, J. BELL, L. JACKSON, P. CASEY, J. SAUNDERS & O. EPSTEIN

Institute for Minimally Invasive Gastroenterology (IMIGE), Royal Free Hampstead NHS Trust, Hampstead, London, UK

Correspondence to:

Professor O. Epstein, Centre for Gastroenterology,

Royal Free Hampstead NHS Trust, Pond Street, London NW3 1SP, UK. Email: o.epstein@medsch.ucl.ac.uk

Present address: Professor O. Epstein, Hampstead Campus, Royal Free and University College Medical School, Pond Street, London NW3 2QG, UK.

¹This Study was performed at the Departments of Gastroenterology and Radiology, Hampstead Campus, Royal Free and University College Medical School, London, UK.

Publication data

Submitted 9 February 2007

First decision 21 February 2007

Resubmitted 13 June 2007

Accepted 18 June 2007

SUMMARY

Aim

To compare virtual colonoscopy with optical colonoscopy findings in symptomatic patients.

Background

Computer tomographic colonography is an alternative to optical colonoscopy. Studies have shown that two-dimensional computer tomographic colonography does not have sufficient sensitivity. Three-dimensional computerized tomographic virtual colonoscopy compares well with optical colonoscopy for colorectal neoplasia screening in asymptomatic individuals.

Methods

One hundred patients aged 50 and older underwent same day virtual colonoscopy and optical colonoscopy. The endoscopists were unaware of the radiologist's report until the withdrawal phase of the endoscopy when segmental unblinding occurred. The virtual colonoscopy and optical colonoscopy findings were compared by using the unblinded optical colonoscopy as the reference standard.

Results

Pancolonic endoluminal virtual colonoscopy was achieved in 99 patients. Optical colonoscopy caecal intubation occurred in 91 patients. Direct comparison was possible in 90 patients. Both techniques revealed the three cancers detected. Virtual colonoscopy revealed 11 polyps ≥ 6 mm diameter in nine patients. Optical colonoscopy revealed 10 polyps ≥ 6 mm diameter in nine patients with a further 15-mm polyp discovered after segmental unblinding.

Conclusion

In symptomatic patients, three-dimensional virtual colonoscopy is equivalent to optical colonoscopy for diagnosing colon cancer and clinically significant polyps. A case can be made for three-dimensional virtual colonoscopy as a primary modality followed if necessary by same day-targeted optical colonoscopy.

Aliment Pharmacol Ther 26, 727–736

INTRODUCTION

In 1966, Overholt reported the first successful total colonoscopy using the 'fiberoptic coloscope'.¹ By the turn of the millennium, optical colonoscopy (OC) was established as the gold standard for imaging the colonic mucosa. OC is a difficult skill to master. The procedure may be painful, almost always requiring i.v. premedication with a combination of opiate analgesia and benzodiazepine sedation. Caecal intubation rates are variable and complications of diagnostic colonoscopy include over-sedation, perforation and procedure related death.^{2,3} These factors weigh heavily when considering that most symptomatic patients undergoing colonoscopy have either a normal study or diverticulosis.

Computerized tomographic (CT) examination of the inflated air or CO₂-filled colon is an attractive alternative. The procedure does not require sedation or analgesia, and a complete examination is almost always possible even in the presence of stenosing cancers. Perforation is extremely rare and the examination provides simultaneous images of the extracolonic organs. If CT scanning had the sensitivity of OC, it might be possible to avoid colonic instrumentation in large numbers of patients. Where a CT study revealed an indication for OC, this could be immediately followed by a preplanned, targeted diagnostic or therapeutic procedure, without the need to visualize the entire organ.

The terms 'virtual colonoscopy' (VC) and 'CT colonography' (CTC) are used interchangeably by many groups to describe CT imaging techniques, which exploit the physical characteristics of gas-filled colon. The terminology reflects the fact that there are several ways in which the gas-filled colon can be viewed by CT. These include a primary review of the two-dimensional (2D) grey scale images reserving three-dimensional (3D) reconstructions for problem-solving or, alternatively, viewing a primary 3D display, which closely resembles the image seen on OC, with 2D images reserved for problem-solving and examining the extracolonic organs. In this paper, we use the term VC to describe exclusively primary 3D virtual reality imaging and distinguish this technique from primary 2D CTC.

Studies comparing CTC with OC in asymptomatic and symptomatic individuals have shown a poor correlation, especially for smaller polyps.⁴⁻⁶ These results differ from a large screening trial using a dedicated VC application.⁷ This study of 1233 individuals indica-

ted that in those aged 50 years and older, VC is at least as sensitive as OC for uncovering cancer and adenomatous polyps greater than 5-mm diameter. The technique has also been shown to detect flat polyps.⁸

Further studies are required to validate the potential value of VC as a primary colonic imaging modality.⁹ This study is the first to compare VIRTUAL COLONOSCOPY software (Viatronix Inc, Stony Brook, NY, USA) with OC in symptomatic gastroenterology out-patients and uses this information to assess the potential impact of VC on diagnostic and therapeutic OC.

PATIENTS AND METHODS

The study protocol was approved by the Hospital Ethics Committee. One hundred patients aged 50 years and older attending general gastroenterology out-patient clinics agreed to participate in the study. All patients were judged to have an indication for colonoscopy, and following a detailed explanation of the study, written consent was obtained. Patients with suspected or documented inflammatory bowel disease were excluded.

For three days prior to the procedure, patients took a low-residue diet. In the 24 h preceding the VC, patients were allowed only clear fluids and were given a single sachet of Picolax (active ingredients sodium picosulphate and magnesium citrate, Ferring Pharmaceuticals, Langley, UK) and 10-mg bisacodyl. To achieve stool tagging, patients consumed 500-mL barium (2% by weight; E-Z-CAT, EZEM, Westbury, NY, USA) during the liquid-only phase of the diet. In addition, colonic fluid was opacified by the administration of 50-mL diatrizoate meglumine and diatrizoate sodium (Gastrografin, Schering Health Care, Burgess Hill, UK). On the day of the CT, they fasted apart from taking a final 50-ml Gastrografin 2 h before study as well as inserting a 10-mg Bisacodyl suppository.

Immediately prior to the CT scan, the colon was inflated with room air using a small flexible non-occluding rectal catheter (Miller Enema Air Tip, EZ-EM Westbury, NY, USA). A prone and supine abdominal CT scan was then performed with a single breath hold (four-slice GE LightSpeed Plus, General Electric Medical Systems, Chalfont St Giles, UK). The CT technique involved the use of 1.25-mm collimation, a table speed of 15 mm/s and a reconstruction interval of 1 mm. The scanner settings of 50 mAs and 120 kV_p gave a calculated total effective dose for combined supine and prone studies of 5.8 mSv.

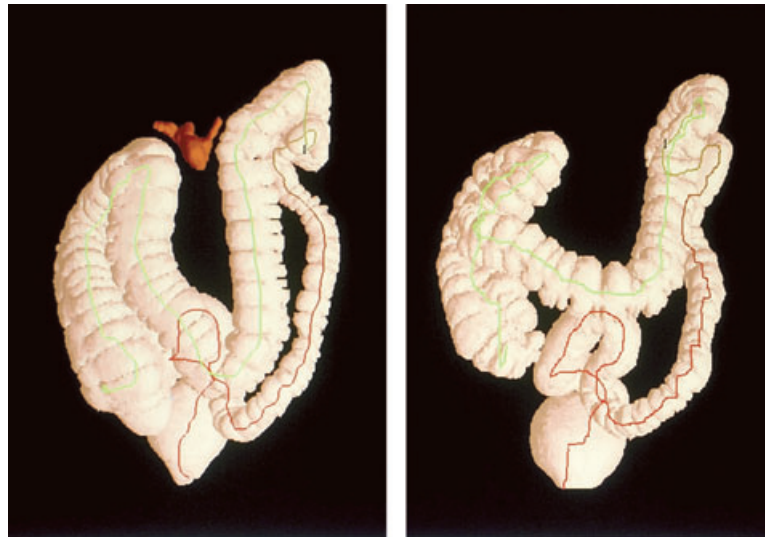

Figure 1. Three-dimensional reconstruction of colon using v3D software.

Image processing was achieved using VIATRONIX v3D COLON (version 1.2) software. This program generates a scout image (Figure 1) and a highly realistic virtual reality 3D colour view of the colonic lumen in approximately 10 min, and calculates an automated ‘fly-through’ centreline from rectum to caecum and back. The primary 3D virtual reality colonic ‘fly-through’ is co-registered with the conventional 2D CTC image, which is instantly accessible from the same screen (Figure 2). When necessary, tagged faeces and liquid were electronically cleansed from both the 3D and 2D images (Figure 3). An experienced gastrointestinal radiologist (J.B.) used the virtual reality 3D image as the primary diagnostic interface and the 2D image was used for

problem-solving. For each patient, a supine and prone fly-through of the whole colon was performed in both directions (i.e. from rectum-to-caecum and caecum-to-rectum). Polyp position was recorded according to colon segment (caecum, ascending colon, hepatic flexure, transverse colon, splenic flexure, descending colon, sigmoid colon or rectum). Mucosal polyps were described as ‘definite’ or ‘very likely’. An uncertain report of ‘possible polyp or faeces’ was considered false positive, if a polyp was not subsequently discovered on OC. Polyp size was recorded on the 3D image using electronic callipers. After assessing the colon, the radiologist recorded extracolonic CT findings, which were graded according to clinical importance by the same

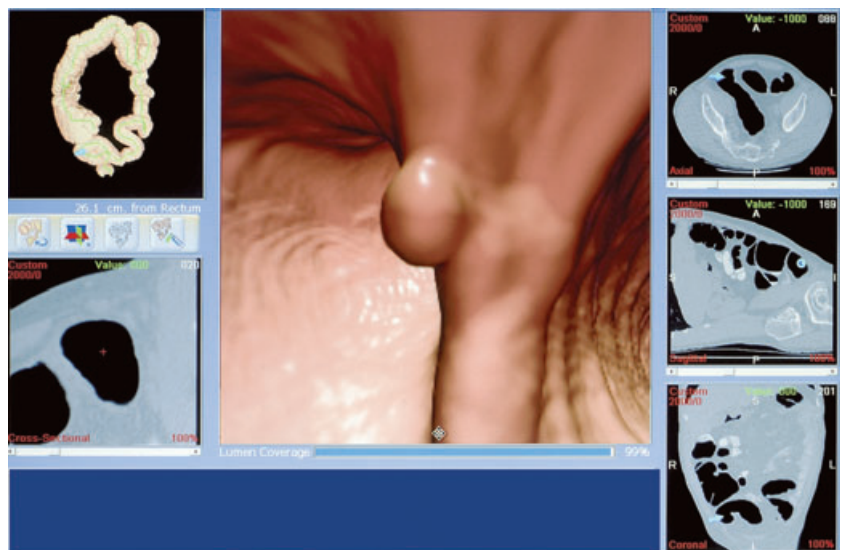


Figure 2. Polyp demonstrated on the v3D workstation.

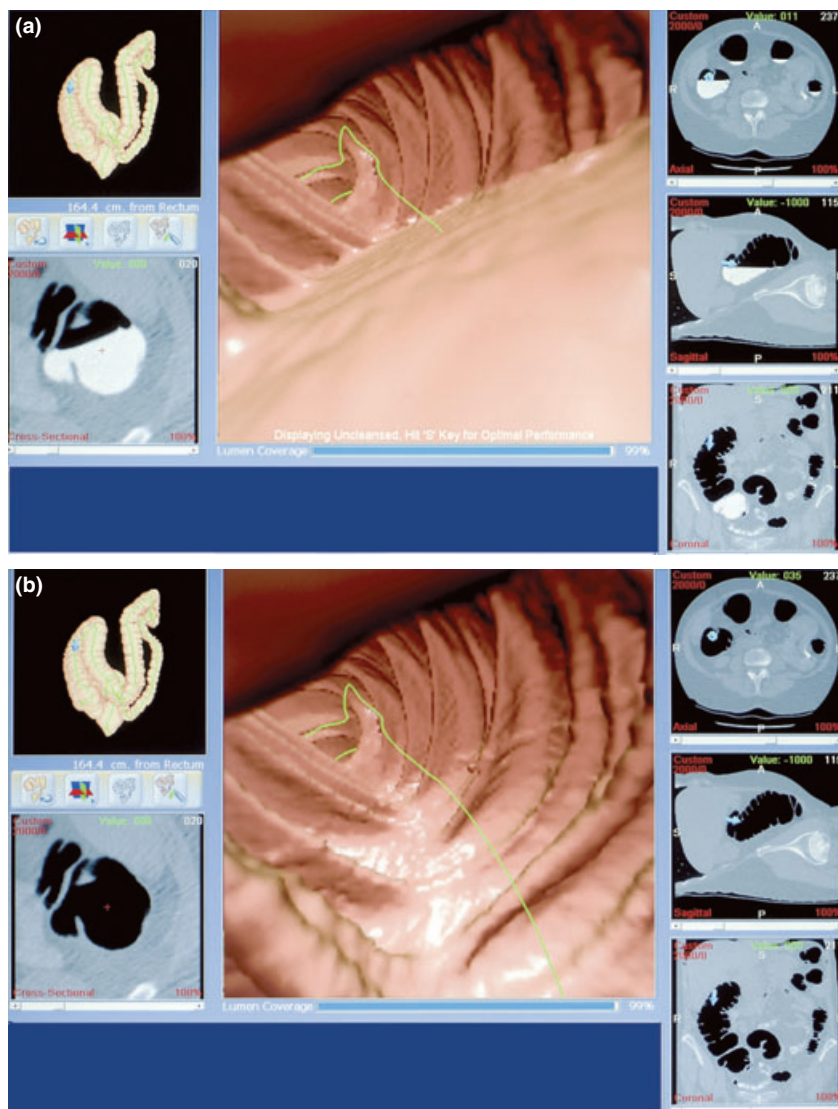


Figure 3. (a) Image illustrating appearance of the colon before electronic cleansing and (b) Image illustrating appearance of the colon after electronic cleansing.

methods as previous studies.^{10, 11} The time for VC included both the time taken for the CT scan and the time to read and report the scan.

The OC followed the VC and was performed by experienced colonoscopists, all of whom had previous audited caecal intubation rates greater than 90%. Prior to the procedure, all patients were sedated with 2.5–5 mg midazolam administered with or without 25–50 mg pethidine analgesia. Olympus EVIS 200 video-colonoscopes were used to inspect the mucosa. All the OC procedures were recorded on digital videotape for later review. The caecum was only positively identified when the ileo-caecal valve was recognized by both the endoscopist and endoscopy nurse. Segmental unblinding was used to correlate OC and VC findings. During the withdrawal phase of the proce-

cedure, the colonoscopist, who was unaware of the VC findings, inspected sequential colonic segments (ascending, transverse, descending, sigmoid and rectum). Following careful inspection of each segment, the study nurse informed the colonoscopist of the equivalent VC findings. If VC reported definite or equivocal finding not seen during the segmental colonoscopy, the segment was carefully re-examined using the VC description for anatomical assistance.

Polyp size was assessed by comparing the polyp dimensions with the maximum jaw width of a fully open biopsy forceps (5 mm). Polyps equal to or smaller than the tips of the open biopsy forceps were termed diminutive polyps (≤ 5 mm), and those greater in size were considered as clinically significant polyps. Spearman's rank correlation test was used to

correlate polyp size judged by VC and OC. Attempts were made to remove and retrieve all polyps irrespective of size and these, as well as biopsies from suspected cancers and other mucosal abnormalities, were sent for histological evaluation. After each colonoscopy, the study nurse asked the endoscopist to assess subjectively the percentage of the mucosa seen during the procedure. The time taken from start to completion of the OC was measured using the video tape timeline. The total time for OC included the time of the procedure and postprocedure time to full recovery and discharge.

Immediately after the VC, and again prior to discharge from the endoscopy unit, patients were asked to indicate on a 10-point scale the tolerability of the preparation and the level of physical discomfort experienced during the procedures.

The final results of OC (corrected for discordant findings by re-examination of colon segments after unblinding) were used as the reference standard with which to compare VC findings with the initial (uncorrected) OC findings. Although polyps, especially those <10-mm diameter, are unlikely to cause symptoms such as altered bowel habit, abdominal pain, rectal bleeding and iron deficiency anaemia, interest was focused on the coincidental discovery of all polyps and in particular those measuring 6 mm or more in diameter. Diminutive polyps were also recorded and biopsied or cold snared.

A polyp-matching procedure was used to address uncertainties in comparative localization and size.⁷ For a reported lesion to be recorded as a true positive match between VC and OC, the lesion had to appear in the same segment or in adjacent segments, and the

two recorded diameters had to be similar (within a 50% margin of error).

RESULTS

The study population included 63 females and 37 males (mean age 63 years). The indications for colonoscopy are summarized in Table 1. Sixty-eight patients had a single reason for examination and 32 had more than one indication.

Mean door-to-door time in the CT scanner was 24.75 min (SD \pm 6.68) and mean VC reporting time was 21.07 (SD \pm 4.99) minutes. Mean time to complete OC was 26.34 min (SD \pm 11.9). Ninety-five per cent of patients discharged from the endoscopy unit between 90 and 180 min after the procedure.

VC was successful in 99 patients and was incomplete in one patient who was unable to retain air. OC was incomplete in eight patients because of technical difficulties including uncontrolled looping, severe sigmoid diverticulosis or pain. In one additional patient, the procedure was abandoned because of profound bradycardia. The OC completion rate was 91%. One patient with an obstructing hepatic flexure carcinoma colon was included in the completed group. Excluding the VC and OC technical failures, there were 90 patients in whom direct comparative examinations were possible.

The VC software calculated that the radiologist inspected >99% of the reconstructed colonic mucosa. Colonoscopists subjectively estimated that they inspected a mean of 89% of the mucosal surface (range: 75–95%). The radiologist considered the 3D view superior to the 2D in 59 patients. In 18 patients, the 3D and 2D

Table 1. Indications for colonoscopy

Indication	No.
Altered bowel habit	28
Abdominal pain	21
Microcytic anaemia	16
Weight loss	13
Family history of colon cancer	11
Constipation	11
Rectal bleeding	10
Diarrhoea	7
Previous polyps	5
Previous colon cancer	3
Miscellaneous	3

were considered equivalent and in 23 patients, the 2D view was required for problem-solving. The comparative cancer and polyp findings on OC (corrected for discordant findings) are summarized in Table 2. VC and OC both detected two rectal and one hepatic flexure carcinomas. Concurrent multiple hepatic metastases were reported on the CT images of one of the patients with hepatic flexure cancer. In this patient, the colon proximal to the tumour could be visualized to the ileocaecal valve by VC but not OC.

For polyps ≥ 6 mm, a good correlation was demonstrated for size of polyp measured on VC and that reported by the colonoscopist (r_s 0.7, $P < 0.02$). In the 90 patients where both VC and OC were complete, VC reported 11 polyps ≥ 6 mm in nine patients. In eight additional patients, 'possible polyp or faeces' ≥ 6 mm were reported. On segmental unblinding, none of these

was shown to be a mucosal polyp (per patient specificity 91%).

First look OC reported 10 polyps ≥ 6 mm in nine patients. In one of these patients, a 15-mm rectal polyp was discovered after segmental unblinding. This polyp was only visible on retroflexion of the colonoscope. Per polyp sensitivity for polyps ≥ 6 mm was 100% for VC and 91% for OC. Of the 11 polyps ≥ 6 mm, nine were retrieved for histology. One polyp adjacent to an obvious cancer was not removed and there was failure to retrieve a second polyp following polypectomy. Of the remainder, seven polyps were simple tubular adenomas, one was a lipoma and there was one inflammatory polyp.

There were 69 diminutive polyps (≤ 5 mm) reported on OC, five of which were discovered on segmental unblinding. Histology was available on 60 diminutive

Table 2. Size, position and histology of cancer and polypoid mucosal lesions retrieved on optical colonoscopy

	≤ 5 mm* (<i>n</i>)	6–9 mm* (<i>n</i>)	≥ 10 mm (<i>n</i>)	Total (<i>n</i>)
Rectum				
Adenoma	3	1	3	7
Carcinoma	–	–	2	2
Non-adenoma	11	1	–	12
Sigmoid				
Adenoma	7	3	–	10
Non-adenoma	13	1	–	14
Descending				
Adenoma	3	–	–	3
Non-adenoma	3	–	–	3
Splenic flexure				
Adenoma	3	–	–	3
Non-adenoma	–	–	–	–
Transverse				
Adenoma	1	–	–	1
Non-adenoma	3	–	–	3
Hepatic flexure				
Carcinoma	–	–	1	1
Ascending				
Adenoma	5	–	–	5
Non-adenoma	4	–	–	4
Caecum				
Adenoma	3	–	–	3
Non-adenoma	1	–	–	1
Total				
Adenoma	25	4	3	32
Carcinoma	–	–	3	3
Non-adenoma	35	2	–	37

*Histology not available in nine polyps < 6 mm and two polyps ≥ 6 mm.

polyps. Of these, 25 (42%) were benign tubular adenomas and 35 (58%) were non-adenomatous. Of the diminutive non-adenomatous polyps, 23 were hyperplastic, three were inflammatory, there were two anal warts, one lipoma, one rectal prolapse and five polyps were reported as histologically normal. Fourteen of the diminutive polyps reported on OC were reported on VC and of the 25 diminutive adenomas retrieved on OC, four were reported as polyps on VC.

A diagnosis of diverticulosis was reported on VC and OC in 36 and 27 patients respectively. Diverticula were reported on both VC and OC in 20 patients and in 16 patients, diverticulosis was only reported on VC. In seven patients, diverticula were seen only on OC. OC findings not visible on VC included three patients with mild colitis, one with melanosis coli and one with caecal angiodysplasia. In the nine incomplete OCs, the only abnormality reported on VC was one patient with diverticulosis.

The standard abdominal CT scans revealed 175 extracolonic findings in 72 patients. Of these, 119 were graded as low significance, 34 as medium significance (including nine patients with undiagnosed gallstones), and 22 as high significance (Table 3).

All patients undergoing both VC and OC responded to the bowel preparation tolerability and discomfort questionnaire. Mean bowel preparation tolerability was 4 (SD \pm 2.18). There was no difference in reported discomfort comparing VC (mean pain score \pm SD, 4.39 \pm 2.2) and OC (mean pain score \pm SD, 4.56 \pm 2.08).

DISCUSSION

In 1994, Vining reported the first attempts at computed tomography colonography.¹² However, progress was hampered by considerable technical challenges

and had to await the simultaneous emergence of new technologies. Multi-detector spiral CT facilitated single breath-hold abdominal scans and affordable fast computers provided the raw power needed for rapid volumetric rendering and 3D image reconstructions. By adding colour and a manual navigation function to the 3D colon reconstruction, a virtual reality image can now be viewed and manipulated as a close simulation of OC.

Studies comparing OC and CTC in symptomatic^{4, 5} and asymptomatic⁶ patients have cast doubt on the value of CTC as a contender for routine colon imaging, mainly because of poor sensitivity for clinically significant polyps. The large VC screening study reported by Pickhardt drew different conclusions.⁷ Using segmental unblinding to correct for polyps missed on first look OC, this study indicated close equivalence between VC and OC for clinically significant polyps. By comparison with 2D CTC, the 3D VC image provides a longer time frame to view polyps and other topographical features. The life-like picture also allows better differentiation of equivocal mucosal abnormalities, such as merging haustral folds, from normal anatomical variants. In addition, stool and liquid tagging allows electronic cleansing thereby reducing confusion between true mucosal lesions and artefact. The software package used also allows the radiologist to select either an automated centrepoint fly-through or a manual flight mode, which uses mouse steering to simulate closely the tip control of a colonoscope. In manual mode, full navigational control allows the viewer to hover over a lesion, zoom and circumnavigate behind folds. A 'paint' application colour codes all the visualized mucosa allowing the viewer to revisit all the mucosal surfaces missed on the initial fly-through. This ensures that >99% of the reconstructed mucosal

Table 3. Highly significant extracolonic findings requiring further investigation

Liver lesions	8
Liver metastases	1
Renal cystic abnormalities	4
Adrenal masses	2
Renal medullary calcinosis	1
Right lung nodule	1
Abdominal aortic aneurysm	1
Suspected endometriosis	1
PUJ obstruction	1
Colovesical fistula	1
Pancreatic mass	1

surface is inspected. The VC software also includes a translucency filter application, which further helps differentiate bowel wall artefact from colonic tissue. Previous studies have shown good inter-observer agreement between gastrointestinal radiologists reading images viewed on this VC software.⁷ There appears to be a rapid learning curve for experienced gastrointestinal radiologists. The VC results in this study were reported by a gastrointestinal radiologist with a previous experience of over 500 CTCs but with personal experience of less than 10 VCs.

This study of symptomatic patients confirms that VC with this software has a high caecal access rate even in patients with stenosing carcinoma. VC failed to outline the entire colon in only one patient. In contrast, technical difficulties and a single serious side effect prevented pan-colonoscopy in nine OCs with a further OC failing to reach more proximal colon because of a stenosing hepatic flexure carcinoma. This study confirms that in patients presenting to gastroenterology out-patients with symptoms suggestive of colonic disease, in this study, VC is as accurate as OC for diagnosing cancer and clinically significant polyps. VC reveals more diverticulosis than OC, probably reflecting the additional air used for colon inflation.

A sample size of 100 patients was chosen on the basis that in a cohort of 100 symptomatic gastroenterology out-patients referred for OC, colon cancer would be expected in two or three patients and polyps >5 mm in approximately 15 patients, half of which would be larger than 10 mm.^{13, 14}

In symptomatic patients aged 50 years and older, both VC and OC detect incidental polyps, most of which are small, benign and unlikely to be the cause of the symptoms. There is debate about the management of polyps ≤ 5 mm,¹⁵⁻¹⁷ Most of these polyps are reported as non-neoplastic or diminutive adenomas.^{18, 19} In OC, experienced colonoscopists miss up to 27% of 1–5 mm polyps.^{20, 21} Both VC and CTC have poor sensitivity for polyps ≤ 5 mm.⁴⁻⁷ and this threshold is confirmed in this study. Limits of detection relate primarily to CT slice thickness.²² The risk of cancer in missed diminutive adenomas is usually regarded as negligible,²³ although in rare instances carcinoma has been recognized.²⁴ Clinical judgement is required to decide whether to ignore diminutive lesions, remove them endoscopically or consider repeating an imaging study three to five years later.

There is consensus that polyps ≥ 6 mm should be removed even if they are incidental and unlikely to be

the cause of symptoms. In OC, experienced colonoscopists miss up to 13% of 6–9-mm polyps and 6% of polyps ≥ 10 mm.^{20, 21} Like Pickhardt's study,⁷ this study indicates that the VC detection rate for polyps ≥ 6 mm is marginally better than OC. This probably relates to the OC blind spots which include the proximal side of folds, the inner aspect of flexures, and the distal rectum.²⁵ On VC there were eight reports of 'possible polyp or faeces' ≥ 6 mm following segmental unblinding, all were considered false positive artefact on OC.

One early perceived weakness of VC was its low sensitivity in detecting flat lesions. Pickhardt *et al.*²⁶ demonstrated that VC detected 83% of flat adenomas and 80% of all flat lesions 6 mm or greater. Park *et al.*²⁷ reported that less than 50% of flat lesions on CTC could be visualized, even after unblinded review. Before they could be visualized, flat lesions were 2 mm or greater in height and 7 mm or greater in diameter. It seems therefore that below 6–7 mm these flat lesions are currently difficult to see on CT, but it is worth noting that advanced histology in such lesions is very rare (0 out of 148 such lesions detected in Pickhardt's study on OC were advanced). Furthermore, flat lesions over 6 mm are uncommon findings at OC in the Western world.

Optical colonoscopy often fails to explain abdominal symptoms. Both CTC and VC studies have demonstrated a high yield of extracolonic findings in asymptomatic and symptomatic gastroenterology patients.^{7, 10, 11} In this study there were 22 extracolonic findings of high significance and 34 of medium significance. This collateral information might add to the clinical assessment of patients presenting with abdominal symptoms where colonoscopy fails to reveal a likely cause.

The preparation used in this study was developed to encourage compliance in asymptomatic individuals⁷ and was well tolerated by the majority of symptomatic patients. The bowel preparation for VC is also suitable for same day follow-on OC. It is of interest that VC and colonoscopy procedures were equally tolerated by patients. VC and CTC are performed without sedation and colonic inflation with room air prior to CT scanning causes transient abdominal discomfort, which is usually relieved soon after the procedure with the passage of wind. Colon inflation with CO₂, which is more rapidly absorbed than air, might improve the discomfort associated with inflation. A CO₂ insufflator was not available in the scanning department at the time of this study but is currently in routine use. All OC patients received sedation with or without opiate

analgesia and this probably played an important role in perception and recollection of the colonoscopy experience.

Gastrografin was used to tag the liquid phase of any colonic residue still present after the bowel preparation. This, together with dilute barium, forms the basis for electronic cleansing.

The decision not to use i.v. contrast in this study was informed by a number of factors. Radiological opinion regarding the routine use of i.v. contrast remains divided; a 2005 consensus study amongst North American CTC experts indicated that 81% did not consider contrast a requirement for VC²⁸ whereas a European consensus statement in 2007 considered routine use justified.²⁹ This study used the validated VC protocol developed by Pickardt where i.v. contrast was not used.⁷ In addition, there is a theoretical disadvantage of using i.v. contrast, as the electronic cleansing algorithm would subtract contrast enhanced polyps, thereby reducing sensitivity.

Bearing in mind the relative simplicity of performing VC, its diagnostic accuracy, the complications of OC and the relatively low yield of OC in both symptomatic patients and individuals undergoing polyp and cancer screening, a case can be made for considering VC as an initial imaging technique. The bowel preparation for VC is highly effective for OC and where further colonic investigation or intervention is indicated, same day targeted biopsy or therapeutic colonoscopy can be arranged to follow on the VC. Using this strategy, only 21 of the 100 patients in this study would have been directed to same day targeted therapeutic or diagnostic colonoscopy. Those requiring optical examination would have included nine patients with 11 clinically significant polyps requiring polypectomy, eight with indefinite polypoid lesions requiring optical assessment, three with cancer requiring biopsy and the one failed VC. In this study, all clinically significant benign polyps were located distal to the splenic flexure and the colonoscopist might have chosen to restrict the therapeutic or diagnostic endoscopy to the left colon. In the two patients with rectal cancer, VC revealed no proximal abnormality and a flexible sigmoidoscopy might have been sufficient to confirm and biopsy the lesion. In the patient with the stenosing hepatic flexure cancer, hepatic secondaries were obvious on the CT scan and routine OC of the ascending colon after surgery might have been avoided as the VC obtained an excellent image of the colon proximal to the malignant stricture.

Virtual colonoscopy with this method is a remarkable new virtual reality imaging technique, which compares well with OC and supersedes standard 2D CTC. The procedure is performed on out-patients without sedation, reveals both colonic and extra-colonic anatomy, carries very little risk of complications and a complete examination is almost always possible. There are concerns about radiation dose, but related risks are likely to fall as the technology develops. Current VC protocols deliver 5–6 mSv, which is equivalent to the exposure from an air contrast barium enema or 2 years of natural background radiation. The patients in this study were aged 50 and over, and all were symptomatic, requiring some form of imaging. The radiation risk of VC needs to be balanced against the risks that accompany alternative procedures such as barium enema or OC.

The results of this, and Pickardt's study, provide a strong case for considering that VC could play a major role as a primary colonic imaging modality in both symptomatic and screening investigation. Just as the safety and sensitivity of magnetic resonance cholangiopancreatography rapidly revolutionized the diagnostic role of the ERCP, the emergence of VC followed, if necessary, by targeted diagnostic or therapeutic colonoscopy offers an exciting new era of minimally invasive colonic imaging.

In our view, the era has arrived where patients can be judiciously offered VC as a credible alternative to diagnostic OC. In addition to offering a primary screening modality, VC should be considered in symptomatic adults where the clinician wishes to exclude polyps, cancer, strictures and diverticulosis as a cause of symptoms, or where OC has failed to reach the caecum. The fly through is also particularly helpful for imaging the colon proximal to a benign or malignant stricture. VC will not establish a diagnosis of angiodysplasia, which accounts for a small percentage of patients with iron deficiency anaemia and is unlikely to have a role in the imaging or diagnosis of ulcerative colitis. A possible role in the staging and investigation of Crohn's colitis is yet to be addressed.

ACKNOWLEDGEMENTS

The V3D Colon workstation was loaned to the Department of Radiology by Vertec Scientific Ltd, Reading, UK. *Declaration of personal and funding interests:* None.

REFERENCES

- 1 Overholt BF, Pollard HM. Cancer of the colon and rectum. Current procedures for detection and diagnosis. *Cancer* 1967; 20: 445–50.
- 2 Bowles CJA, Leicester R, Romaya C, Swarbrick E, Williams CJ, Epstein O. A prospective study of colonoscopy practice in the UK today: are we adequately prepared for national colorectal cancer screening tomorrow? *Gut* 2004; 53: 277–83.
- 3 Wayne JD, Kahn O, Auerbach ME. Complications of colonoscopy and flexible sigmoidoscopy. *Gastrointest Endosc Clin N Am* 1996; 6: 343–77.
- 4 Cotton PB, Durkalski VL, Pineau BC, *et al.* Computed tomographic colonography (virtual colonoscopy): a multicentre comparison with standard colonoscopy for detection of colorectal neoplasia. *JAMA* 2004; 291: 1713–9.
- 5 Rockey D, Paulson E, Niedzwiecki D, *et al.* Analysis of air contrast barium enema, computer tomographic colonography, and colonoscopy: prospective comparison. *Lancet* 2005; 365: 305–11.
- 6 Johnson CD, Harmsen WS, Wilson LA, *et al.* Prospective blinded evaluation of computed tomographic colonography for screen detection of colorectal polyps. *Gastroenterology* 2003; 125: 311–9.
- 7 Pickhardt PJ, Choi JR, Hwang I, *et al.* Computed tomographic virtual colonoscopy to screen for colorectal neoplasia in asymptomatic adults. *N Engl J Med* 2003; 349: 2191–200.
- 8 Pickhardt PJ, Nugent PA, Choi JR, Schindler WR. Flat colorectal lesions in asymptomatic adults: implications for screening with CT virtual colonoscopy. *Am J Roentgenol* 2004; 183: 1343–7.
- 9 Halligan S, Atkin W. Unbiased studies are needed before virtual colonoscopy can be dismissed. *Lancet* 2005; 365: 275–6.
- 10 Hara AK, Johnson CD, MacCarty RL, Welch TJ. Incidental extracolonic findings at CT colonography. *Radiology* 2000; 215: 353–7.
- 11 Gleucker TM, Johnson CD, Wilson LA, *et al.* Extracolonic findings at CT colonography: evaluation of prevalence and cost in a screening population. *Gastroenterology* 2003; 124: 911–6.
- 12 Vining DJ, Gelfand DW, Bechtold RE, *et al.* Technical feasibility of colon imaging with helical CT and virtual reality. *Am J Roentgenol* 1994; 162(Suppl.): 104.
- 13 Lieberman DA, De Garmo PL, Fleisher DE, Eisen GM, Chan BKS. Colonic neoplasia in patients with nonspecific GI symptoms. *Gastrointest Endosc* 2000; 51: 647–51.
- 14 Pepin C, Ladabaum U. The yield of lower endoscopy in patients with constipation: survey of a university hospital, a public county hospital, and a Veterans Administration medical center. *Gastrointest Endosc* 2002; 56: 325–32.
- 15 Dachman AH, Yoshida H. Virtual colonoscopy: past, present, and future. *Radiol Clin North Am* 2003; 41: 377–93.
- 16 Bond JH. Clinical relevance of the small colorectal polyp. *Endoscopy* 2001; 33: 454–7.
- 17 Kulling D, Christ AD, Karaaslan N, Fried M, Bauerfiend P. Is histological investigation of polyps always necessary? *Endoscopy* 2001; 33: 428–32.
- 18 Macari M, Bini EJ, Jacobs SL, *et al.* Significance of missed polyps at CT colonography. *Am J Roentgenol* 2004; 183: 127–34.
- 19 Pickhardt PJ, Choi JR, Hwang I, Schindler WR. Nonadenomatous polyps at CT colonography: prevalence, size distribution, and detection rates. *Radiology* 2004; 232: 784–90.
- 20 Rex DK, Cutler CS, Lemmel GT, *et al.* Colonoscopic miss rates of adenomas determined by back-to-back colonoscopies. *Gastroenterology* 1997; 112: 24–8.
- 21 Hixson LS, Fennerty MD, Sampliner RE, *et al.* Prospective study of the frequency and size distribution of polyps missed by colonoscopy. *J Natl Cancer Inst* 1990; 82: 1769–72.
- 22 Taylor SA, Halligan S, Bartram CI, *et al.* Multi-detector row CT colonography: effect of collimation, pitch, and orientation on polyp detection in a human colectomy specimen. *Radiology* 2003; 229: 109–18.
- 23 Nusko G, Mansmann U, Partzsch U, *et al.* Invasive carcinoma in colorectal adenomas: multivariate analysis of patient and adenoma characteristics. *Endoscopy* 1997; 29: 626–31.
- 24 Church JM. Clinical significance of small colorectal polyps. *Dis Colon Rectum* 2004; 47: 481–5.
- 25 Pickhardt PJ, Nugent PA, Mysliwiec PA, Choi JR, Schindler DO. Location of adenomas missed by optical colonoscopy. *Ann Intern Med* 2004; 141: 3525–9.
- 26 Pickhardt PJ, Nugent PA, Choi JR, *et al.* Flat colorectal lesions in asymptomatic adults: implications for screening with CT virtual colonoscopy. *AJR* 2004; 183: 1343–7.
- 27 Park PSH, Ha HK, Kim AY, *et al.* Flat polyps of the colon: detection with 16-MDCT colonography – preliminary results. *Am J Roentgenol* 2006; 186: 1611–7.
- 28 Barish MA, Soto JA, Ferrucci JT. Consensus on current clinical practice of virtual colonoscopy. *AJR* 2005; 184: 786–92.
- 29 Taylor SA, Laghi A, Lefere P, Halligan S, Stober J. European society of gastrointestinal and abdominal radiology (ESGAR): consensus statement on CT colonography. *Eur Radiol* 2007; 17: 575–9.